

## Bone grafting with simultaneous early implant placement

# A new approach with an in-situ self-hardening grafting material

MINAS LEVENTIS<sup>1,2</sup>, PHD; PETER FAIRBAIRN<sup>1,3</sup>, BDS; ORESTIS VASILIADIS<sup>2,4</sup>, DDS

The thickness of the buccal plate seems to have a significant influence on the amount of horizontal and vertical crestal resorption in human sockets, while the placement of an implant into the extraction socket with simultaneous implementation of bone regeneration procedures is routinely followed in an attempt to limit the resorption process and preserve the architecture of the alveolar ridge. This case report highlights the management of an upper central incisor post-extraction site with a defective thin residual buccal plate, where an early implant placement procedure, with simultaneous intentional removal of the residual buccal bone and bone augmentation, was performed. The rationale and results of removing the thin buccal bone and using an in situ hardening synthetic bone substitute composed of beta tri-calcium phosphate ( $\beta$ -TCP) and calcium sulfate (CS) to regenerate the area are analyzed and discussed.

### Introduction

Following the extraction of the root from the alveolar socket, the buccal and lingual walls, which are mostly composed of bundle bone, will undergo substantial resorption, as a result of lack of supporting and nutritive function of the tooth and the periodontal ligament following their removal. This remodeling process, as described by several animal and human studies, will lead to severe bone loss, which predominantly involves the buccal aspect rather than the lingual aspect of the site [1-5].

Although it has been suggested that immediate or early placement of implants into extraction sockets may preserve the bony architecture, it has been demonstrated that the implant placement by itself into extraction sockets is not able to halt this remodeling process,

and hence cannot adequately prevent the resorption of the buccal bony wall following tooth extraction [6-9].

Among the factors affecting the remodeling process of post-extraction sockets, the integrity and the thickness of the buccal plate seem to have a significant influence on the amount of resorption in human sockets. The thickness of the buccal bone crest markedly influences the bone fill that occurs in the void (defect) between the implant surface and the socket wall. Thus, sites with thin bony walls ( $\leq 1$  mm) seem to undergo higher resorption following tooth extraction, than sites with thicker buccal plate ( $> 1$  mm). As in the majority of extraction sites in the anterior maxilla, thin and possible defective buccal walls are present, it can be concluded that in most clinical scenarios of immediate or early

implant placement, the buccal bone will undergo pronounced resorption, and additional augmentation procedures are needed to achieve adequate bony contours around the implant [10-12].

### Case report

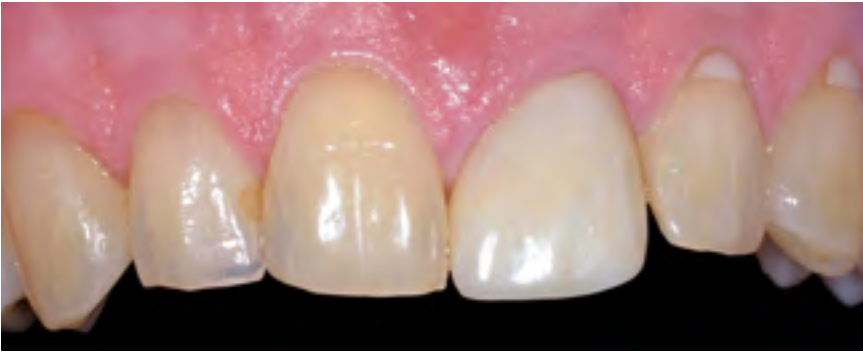A 56-year-old male patient presented with mobility of the upper left central incisor. Clinically, tooth 21 was restored with a metal-ceramic crown which was mobile, with no signs of inflammation or infection in the area (Fig. 1), while radiological examination with a periapical x-ray revealed a vertical root fracture with no evidence of pathology in the surrounding bone (Fig. 2). Given the non-contributory medical history of the patient, and absence of other contraindications, it was decided to replace the fractured tooth with an implant.

<sup>1</sup> Private Practice, London, UK

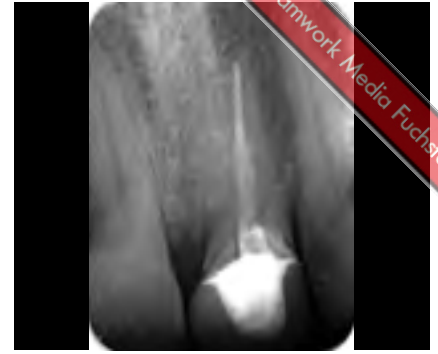<sup>2</sup> Researcher, Laboratory of Experimental Surgery and Surgical Research N. S. Christeas, Medical School, University of Athens, Greece

<sup>3</sup> Visiting Professor, Department of Periodontology and Implant Dentistry, School of Dentistry, University of Detroit Mercy, Detroit, USA

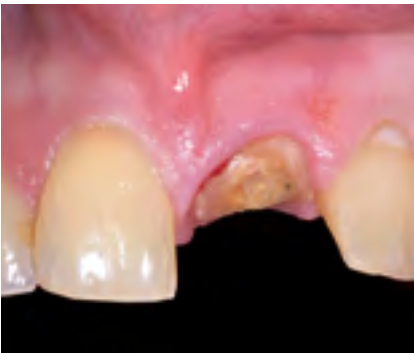<sup>4</sup> Private Practice, Bad Dürkheim, Germany



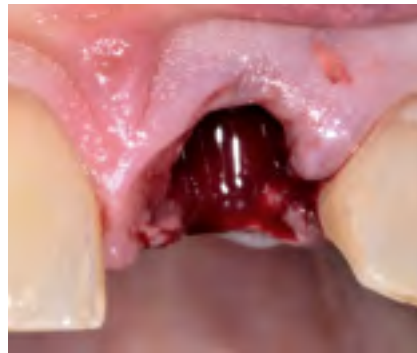1 | Initial clinical view.



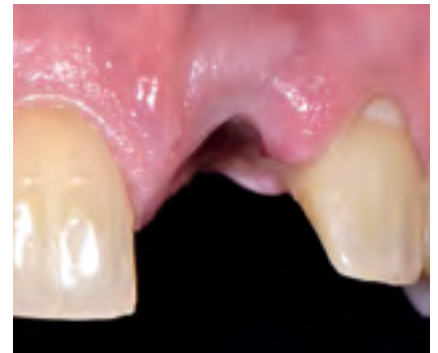2 | Initial x-ray revealing the vertical root fracture.



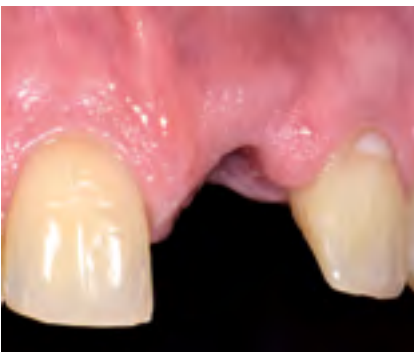3 | Clinical view of the fractured root after removing the crown.



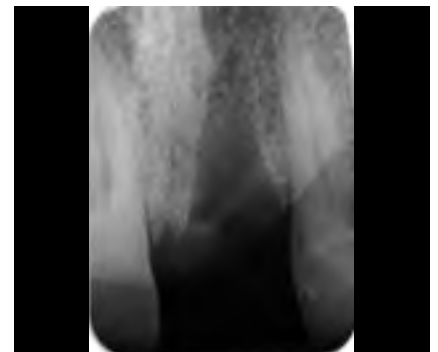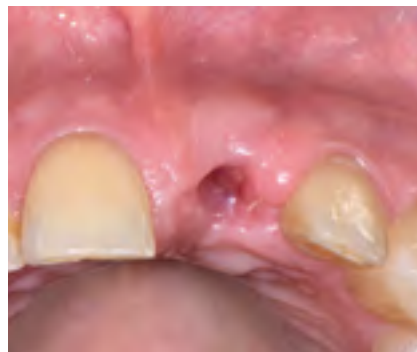4 | Clinical view of the site immediately after "atraumatic" extraction. Note the vertical mattress suture placed to stabilize the distal papilla.



5 | Uneventful secondary intention healing one week post-extraction.



6a and b | Clinical views four weeks after extraction showing excellent healing. The socket is covered by a thin layer of newly-formed soft tissues.



7 | Periapical radiograph four weeks after extraction.

The treatment plan consisted of simple extraction, early implant placement with simultaneous bone augmentation four weeks after extraction, and loading of the implant twelve weeks post-op with the final restoration, according to a simplified standardized protocol [13].

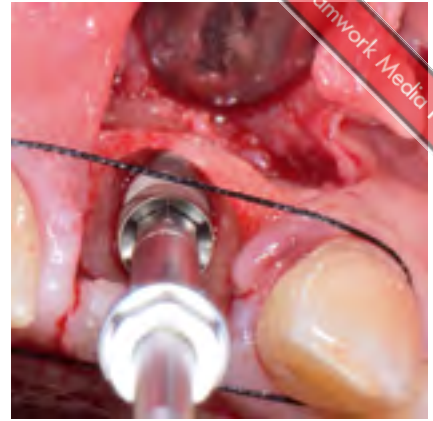
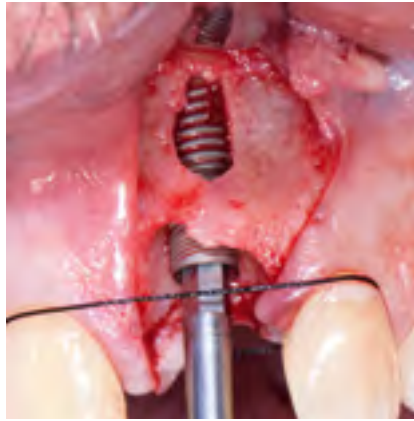Under local anesthesia, the non-restorable tooth was "atraumatically" extracted without raising a flap. Firstly, the crown was removed using forceps (Fig. 3) and the broken root was care-

fully mobilized and removed using periosteal elevators and thin elevators. Attention was given not to damage the surrounding soft and hard tissues. After extraction, the socket was thoroughly curetted and debrided of any soft tissues with the use of Lucas hand bone curettes and degranulation burs (Ethoss EK Strauss Degranulation Bur Kit; Ethoss Regeneration Ltd, Silsden, UK), followed by rinsing with sterile saline. A vertical 5-0 mattress suture (Vicryl, Ethicon; Johnson & Johnson,

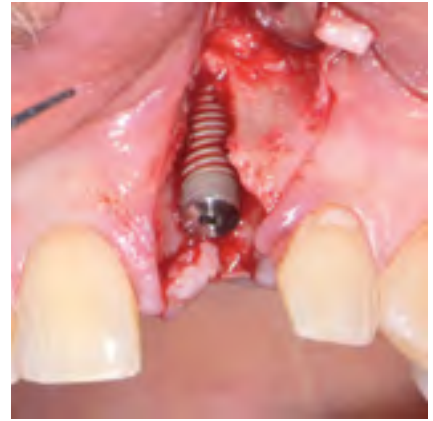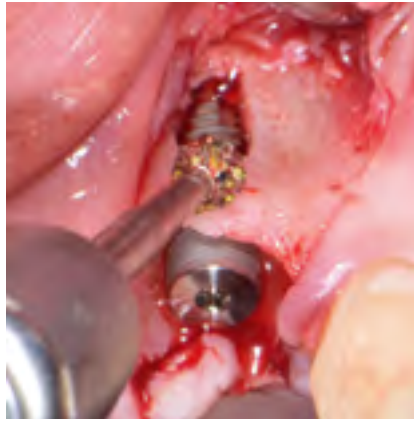Somerville, NJ, USA) was placed to stabilize the distal papilla, and the post-extraction site was then allowed to heal by secondary intention (Figs. 4 and 5). The patient used an acrylic partial denture as a provisional prosthesis during the whole healing period, but without applying pressure on the surgical site.

After four weeks, clinical (Figs. 6a and b) and radiological (Fig. 7) examination showed uneventful healing of the site. Under local anesthesia, a site-

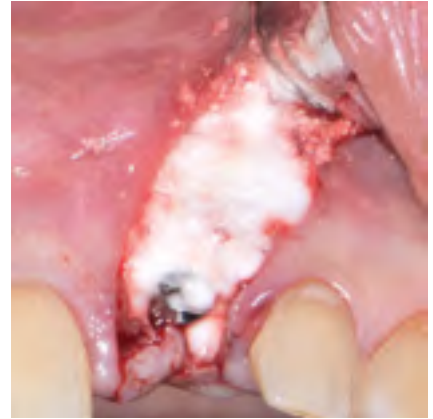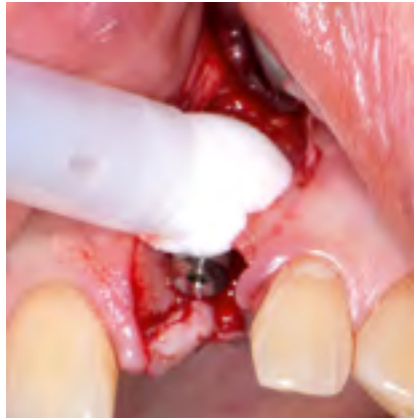8a and b | Placement of the Paltop Advanced Plus implant. A suture placed around the cervical margins of the adjacent teeth help the precise free hand 3D positioning of the fixture.



9a and b | The thin defective buccal bone plate was completely removed.



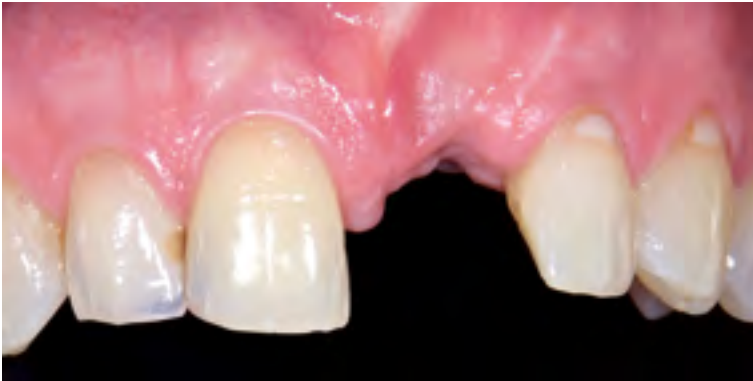10a and b | The site was grafted with  $\beta$ -TCP/CS (EthOss). The bone substitute was injected directly from the carrier syringe, and set in situ. Attention was given not to overfill the site. No additional barrier membranes were used.



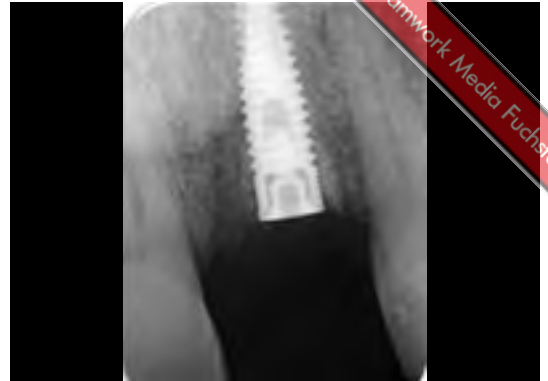specific full thickness flap was raised using vertical releasing incisions, without including the papillae of the adjacent teeth. After flap elevation, all granulation tissue was removed from the site, revealing a thin fenestrated buccal bone plate. A 3.75 mm x 13 mm tapered implant (Paltop Advanced Plus; Paltop Dental Solutions Ltd, Israel) was placed at the optimal position (Figs. 8a and b), and the residual buccal bone plate was completely removed (Figs. 9a and b) using the degranulation burs in high speed

(2500 RPM, which is the indicated speed for alveoloplasty) under copious irrigation with sterile saline. After placing the cover screw, the site was augmented utilizing a self-hardening resorbable synthetic bone grafting material (EthOss; Ethoss Regeneration Ltd, Silsden, UK), as described by the authors in previous publications [13-15]. The grafting material comes in a delivery syringe where the piston is drawn back and sterile saline is added to the powder. It is allowed

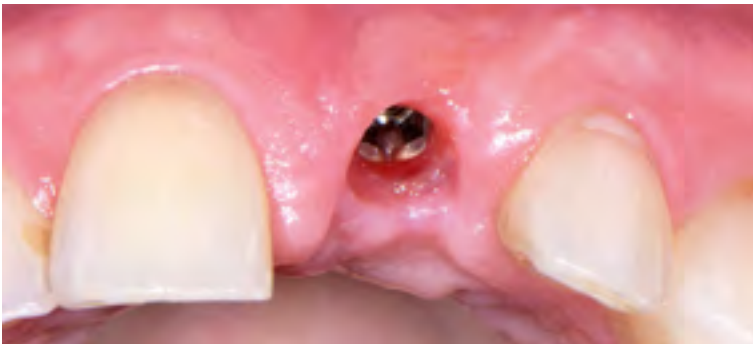to seep through the particles and then the excess is discarded by compression into a sterile gauze. The hydrated material is now taken to the surgical site and extruded into the defect, then compressed with another sterile gauze using an instrument to pack the material into any cavities. The gauze is then held over the graft for three to four minutes until the CS element sets, making sure to restrict the adjacent blood to the material site and remembering not to overfill the site for tension free closure. No barrier



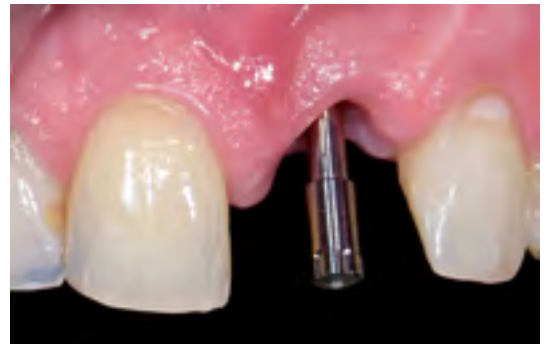11 | Clinical view after ten weeks post-op.



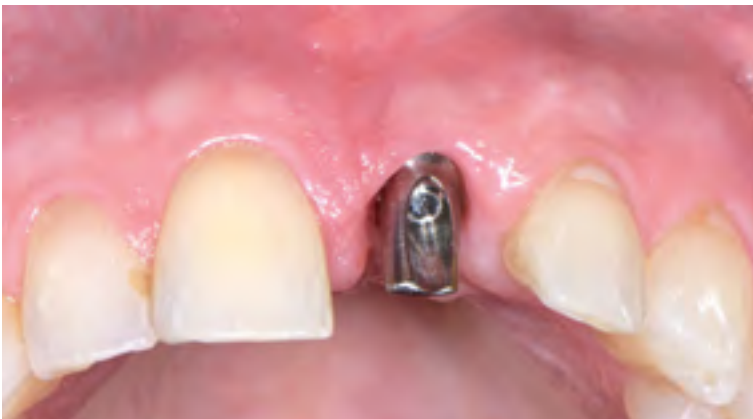12 | Periapical x-ray view after ten weeks post-op.



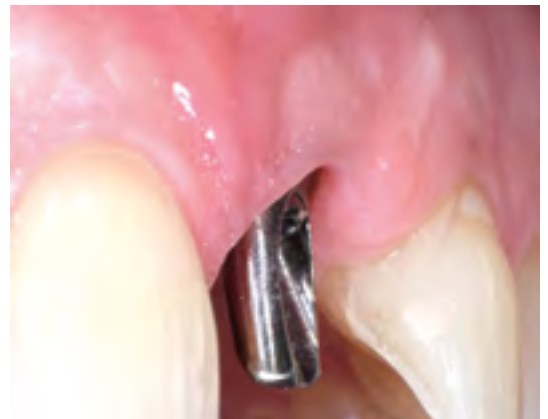13 | Maturation of the soft tissues two weeks after placement of the healing abutment.



14 | ISQ measurement with Penguin.



15a and b | Final abutment placed. Note the preservation of the architecture of the site.

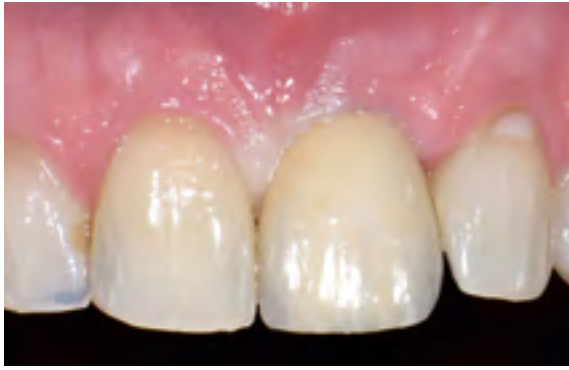

membranes were used (Figs. 10a and b). The mucoperiosteal flap was repositioned and sutured without tension with 5-0 sutures (Prolene, Ethicon; Johnson & Johnson, Somerville, NJ, USA). Antibiotic therapy consisting of 500 mg amoxicillin every eight hours for five days and mouth rinsing with 0.2% chlorhexidine every eight hours for ten days were prescribed. The sutures were removed after a seven-day healing period.

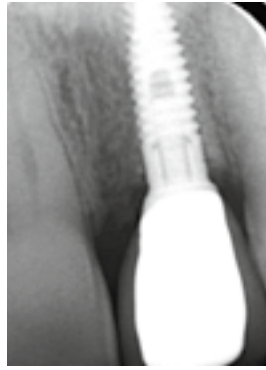
After ten weeks, the healing was uneventful. The architecture and the

dimensions of the ridge were adequately preserved and the site was covered with thick keratinized epithelium (Fig. 11). A periapical x-ray showed excellent osseointegration of the implant and consolidation of the grafting material (Fig. 12). A linear crestal incision was made to access and remove the cover screw, and the secondary stability of the implant was measured by resonance frequency analysis (Penguin; Integration Diagnostics Sweden AB, Göteborg, Sweden). An ISQ-value (Implant Stability Quotient)

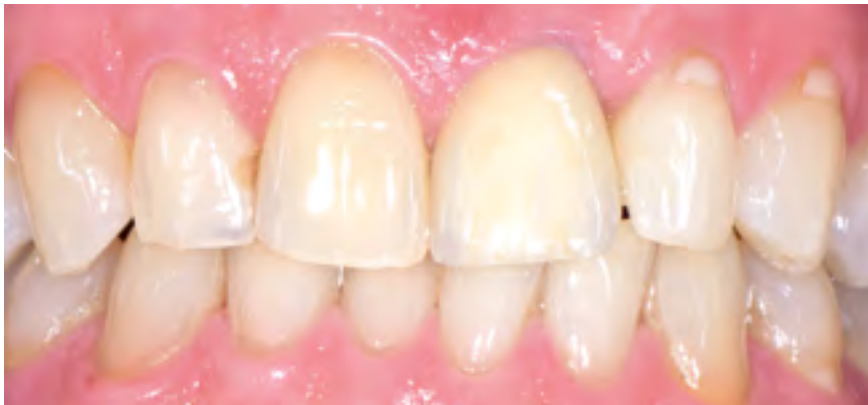of 72 was recorded, demonstrating high stability. An open-tray impression was taken and a healing abutment was placed. After allowing the soft tissues to mature for two weeks (Fig. 13), the ISQ was recorded again (Fig. 14) revealing again excellent stability of the implant, the final titanium abutment was placed (Figs. 15a and b) and torqued at 35 Ncm, and a metal-ceramic restoration was cemented resulting to a successful outcome regarding aesthetics and function (Figs. 16 to 18, see next page).



16 | Final crown fitted.



17 | Final periapical x-ray.



18 | Clinical view at two weeks follow-up.

### Discussion

In the presented case, we decided to intentionally surgically remove the residual thin and defective buccal plate, in an attempt to enhance and accelerate the healing of the site. The presence of the thin buccal plate will trigger locally an osteoclastic activity in order to be resorbed and removed from the body, as this residual bundle bone has lost its functional support from the root, and its nutrition from the periodontal ligament. So, it can be assumed that this osteoclastic activity will interfere and probably slow down the bone regeneration in the site which is the goal of our treatment. Moreover, this resorbing thin buccal plate will isolate the periosteum from the surface of the grafting material during the first important stages of healing. Periosteum has been shown to play a pivotal role in bone graft incorporation and healing, as it contains multipotent stromal mesenchymal stem cells that are capable of differentiating into bone and cartilage, and provides a

source of blood vessels and growth factors [16-18], so it can be postulated that the direct contact of the graft with intact periosteum is important and beneficial.

It could be argued that such residual bone should be kept in situ in order to provide mechanical stability to the underlying graft. However, adding CS to  $\beta$ -TCP produces an in situ self-hardening grafting material that may not need additional stabilization with the use of membranes or other meshes [19,20]. Moreover, the CS can act as a barrier, halting the ingrowth of soft tissue during the early phases of bone regeneration [19].

Placement of the implant and the grafting material at four weeks after the extraction takes advantage of the enhanced and activated host bone-healing environment of the post-extraction site [10]. Also, it has been found that the implant itself, due to its semi-conductive nature, increases local bone metabolism and plays a part in the host hard tissue regeneration [21]. Among bone

grafting substitutes,  $\beta$ -TCP is commonly used in clinical practice, and extensively used and researched by the authors [13-15,22-27].

It is important that apart from being osteoconductive, there is strong experimental evidence that calcium phosphates, and  $\beta$ -TCP in particular, have also osteoinductive properties. Although the underlying mechanism remains largely unknown, it has been shown that these synthetic materials can stimulate osteogenic differentiation of stem cells in vitro and bone induction in vivo [28,29].

The above properties of  $\beta$ -TCP and CS grafts might explain the successful use of such bone substitutes for the fast regeneration of high quality vital bone and long-term stability, when used in cases of implants placed into defective extraction sockets. The successful outcomes as seen in the presented case are in accordance with published data by the authors and others [30-32].

In conclusion, when considering the immediate or early installation of implants into extraction sockets, clinicians should consider the thickness of the residual buccal bony walls, and the vertical as well as the horizontal positioning of the implants into the sockets, as these factors might strongly influence hard tissue changes during healing. Moreover, clinicians should be familiarized with the surgical protocols and methods that they employ, and at the same time they should have thorough understanding of the healing processes of the body and knowledge of the specific properties of the grafting materials that they use, in order to control and enhance the biologic mechanisms of regeneration in each individual implant case, and thus achieve successful and predictable results. ■

The references are available at [www.teamwork-media.de/literatur](http://www.teamwork-media.de/literatur)

### Contact address

Dr Peter Fairbairn  
67 Earls Court Road  
Kensington, W8 6EF London  
United Kingdom  
[peterdent66@aol.com](mailto:peterdent66@aol.com)